

United Kingdom Beryllium Registry: Mortality and Autopsy Study

W. Jones Williams

Section of Respiratory Medicine, University of Wales College of Medicine, South Glamorgan, United Kingdom

This report is based on 30 deaths from chronic beryllium disease (CBD) in the United Kingdom with details of 19 autopsies. The majority were fluorescent lamp workers and machinists who died from respiratory failure. There were no cases of lung cancer. The survival times ranged from less than 1 to 29 years and was longest in machinists. All of the workers showed interstitial pulmonary fibrosis with varying degrees of cystic change. The majority showed hyalinized, and a few active sarcoid-type, granulomas. Extrathoracic granulomas, as in a U.K. sarcoid autopsy series, were rare. A notable difference was the absence of myocardial involvement in CBD compared to an incidence of 20% in the sarcoid autopsies. The detection of beryllium in the criteria for diagnosis is emphasized and the cases classified as definite include 12 of 19 positive analysis, 6 of 19, negative or unavailable analysis. The remaining case was classified as dubious because, despite a positive analysis, granulomas were absent. The main differential diagnosis is sarcoidosis. — *Environ Health Perspect* 104(Suppl 5):949–951 (1996)

Key words: autopsy, chronic beryllium disease, granuloma, diagnostic criteria, sarcoidosis

Introduction

Detailed autopsy studies of chronic beryllium disease (CBD) are few and very incomplete. In the majority, histology was only available from the lungs or hilar glands. Previous reports have often been duplicated and autopsy findings often have not been distinguished from biopsies.

The present report is based on 30 deaths from the United Kingdom Beryllium Case Registry (1), which now totals 69 proven and probable cases including seven cases with skin lesions only. The United Kingdom Registry includes all cases of beryllium and suspected beryllium disease referred to or known to the author that occurred in the United Kingdom between 1945 and 1993. Entry to the registry is

dependent on proven beryllium exposure and clinical–radiological features. Details will be presented of 19 autopsies, 2 previously published (2,3) and 5 published during life (4–9). Due to the paucity of material, the present findings are combined with the few relevant reports from other countries, mainly the United States (10–15), Spain (16), Germany (17), and Finland (18).

The pathology of the lungs and hilar glands will be described, together with the distribution of extrathoracic granulomas, the latter compared to findings in the United Kingdom series of 30 sarcoid autopsies (19).

Finally, the criteria for diagnosis of CBD in the series will be delineated along with the differential diagnosis from sarcoidosis (1).

Mortality Study

The majority of the 30 deaths were in fluorescent lamp workers: 13 were involved in manufacturing, experimental development, and disposal; 9 were metal machinists working with pure beryllium metal and mainly beryllium alloys; the remaining 8 included 2 millers, 2 foundry workers, 1 ceramic worker, 1 air sampler, 1 ore crusher, and 1 carpenter in a beryllium machine shop.

The majority (25 of 30) died from respiratory failure and 5 from unrelated causes: coronary thrombosis, 1; cirrhosis, 1; perforated duodenal ulcer, 1; carcinoma of the prostate, 1; and carcinoma of the stomach, 1. The survival times, onset of disease to death, ranged from 2 to 29 years and, though not statistically significant, machinists were the longest survivors (Table 1). There was no relationship between survival time, length of exposure, and lag period before developing disease (data not shown). There are no data for level of exposure, but the longest survivor, 29 years, was a metal machinist with high tissue levels during life and extensive skin, lymphatic, and lung disease (20).

Pulmonary Pathology

As expected from the long survival time, all patients showed end-stage interstitial fibrosis with varying degrees of cystic, honeycomb change (Figure 1). None showed any active interstitial inflammation. The fibrosis tended to be most marked in the upper zones, although it could affect the whole lung and, in less severe cases, the peripheral zones. All were associated with pleural thickening.

Four cases showed intercavity mycetomas (aspergillus infection), an expected complication of long standing disease and steroid therapy. In five cases, palpable nodular scars, up to 2 cm in diameter, were present.

This paper was presented at the Conference on Beryllium-related Diseases held 8–10 November 1994 in the Research Triangle Park, North Carolina. Manuscript received 29 April 1996; manuscript accepted 11 July 1996.

The author thanks many pathologists in the United Kingdom for access to this valuable and unique material.

Address correspondence to Professor W. Jones Williams, Section of Respiratory Medicine, University of Wales College of Medicine, Llandough Hospital, Penarth, South Glamorgan, CF64 2XX, United Kingdom. Telephone: 01222 705187. Fax: 01222 712284.

Abbreviations used: CBD, chronic beryllium disease; LAMMS, laser microprobe mass spectrometry; BeLT, beryllium lymphocyte transformation.

Table 1. Survival time of patients previously exposed to beryllium.

Occupation, no. cases	Survival time, years						Not known
	0–5	6–10	11–15	16–20	21–25	26–30	
Fluorescent lamp workers, 13	2	3	2	0	2	2	2
Machinists, 9	—	2	1	2	2	1	1
Others, 7							
Ceramic worker, 1			1				
Ore crusher, 1		1					
Air sampler, 1	1						
Foundry workers, 2				1	1		
Millers, 2	1	1					
	2	2	1	1	1		1

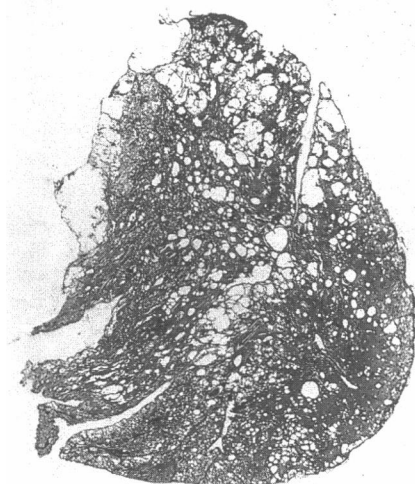


Figure 1. Large section: lung of fluorescent lamp worker showing cystic changes.

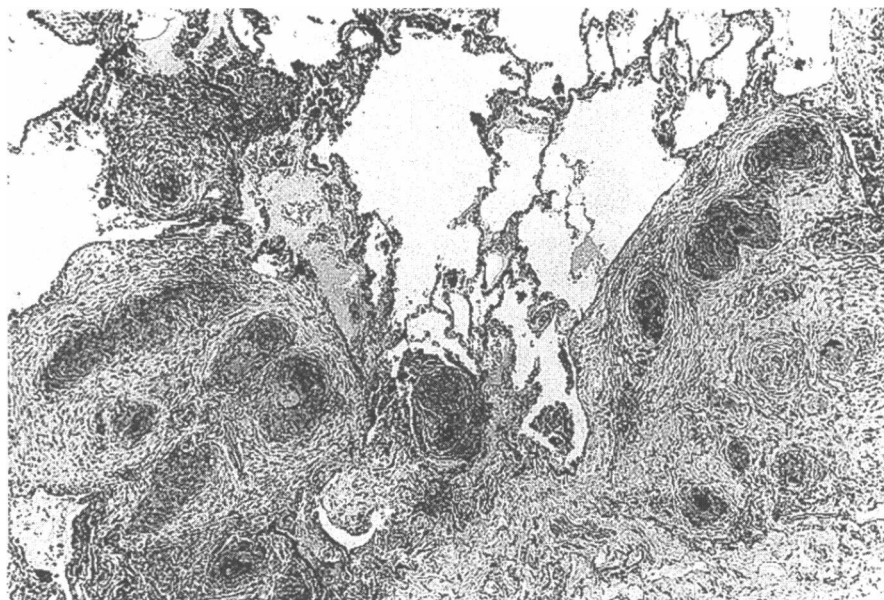


Figure 2. Active and hyalinizing granulomas.

The large nodules consisted of solid masses of hyalinized fibrous tissue with scanty remnants of granulomas and Schaumann bodies. With one exception all showed widespread, mainly hyalinized sarcoid-type and, in six cases, persisting active cellular granulomas (Figure 2). None showed epithelial atypia, tumorlets, or cancer.

Schaumann bodies were found in the majority, 15 of 19 cases, and were very numerous in 3 (Figure 3). They are a useful marker of preexisting granulomas in otherwise nondiagnostic nodular scars, but are not specific for CBD since they are equally common in sarcoidosis (21).

Hilar Lymph Nodes

Histology was available in 10 of 19 cases. As in the lung, the majority showed hyalinized granulomas. In 3 cases, the glands were completely replaced by confluent hyaline scarring with scattered Schaumann bodies.

Extrathoracic Granulomas

In the present and previous reports (Table 2) information is scanty; in the majority of cases, histology was only available from the main center of interest—lungs and hilar lymph nodes. With one exception, involving the brain (15) the lesions were asymptomatic with isolated granulomas in the various organs. Lymph-node granulomas have been found in cervical and mesenteric glands. Granulomas were absent in the bone marrow of 5 patients, thyroid of 3, testis of 2, GI tract of 2, and prostate of 1.

In a comparison of the presence of granulomas in CBD and sarcoid autopsies

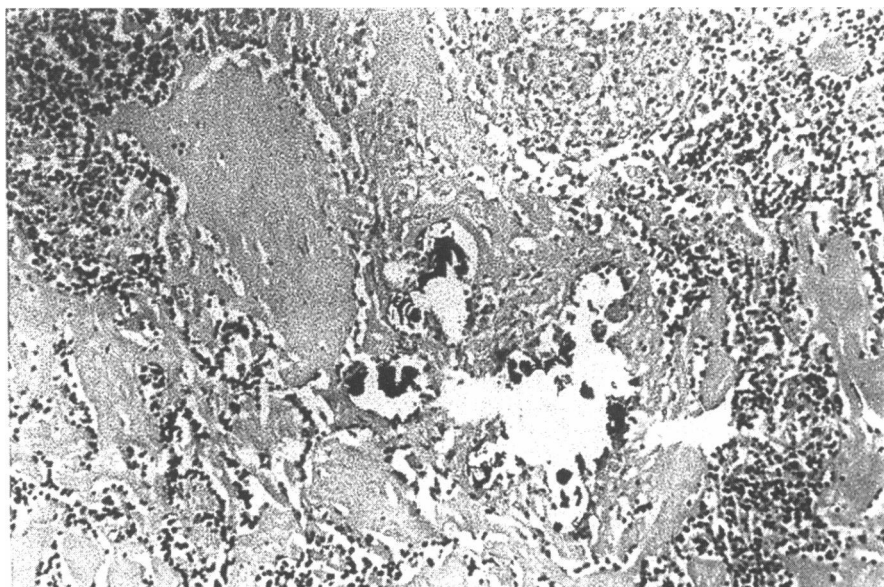


Figure 3. Schaumann bodies in hyalinized scar tissue.

(19) (Table 3) the most notable difference is the absence of myocardial granulomas in CBD (zero of seven cases) compared to a high incidence in sarcoidosis (8 of 30). This reflects the well-recognized cardiac involvement, sometimes causing sudden death, in sarcoidosis (29) but never recorded in CBD. The liver appears to be equally affected but, again, as in CBD, this organ is usually asymptomatic. Splenic granulomas are more common in sarcoidosis, while renal granulomas are uncommon in both. This suggests that the reported

Table 2. Autopsy results: extra-thoracic granulomas.

Organ	Disease: cases found/number examined		
	CBD		Sarcoidosis
	Present series	Others	Jones Williams 1992
Liver	1/6	5/13	16/30
Lymph nodes	1/3	3/5	—
Spleen	0/3	2/11	11/30
Kidney	0/6	2/9	2/30
Brain	0/4	1/6	—
Adrenals	0/3	1/4	—
Pancreas	0/1	1/3	—
Myocardium	0/6	0/7	8/30

Table 3. Autopsy comparison of CBD/sarcoidosis.

Patient parameters	CBD, % (n = 19)	Sarcoidosis, % (n = 30)
History of beryllium exposure	100	0
Myocardial granuloma	0/7	27
Positive beryllium analysis	92	0
Beryllium sensitization	70	0
Honeycomb lungs		
Granulomas	100	100
sarcoidosis, beryllium		
Mycetoma	21	10

high incidence (10%) (23) of renal calculi in CBD, as in sarcoidosis, is unrelated to the presence of granulomas.

Criteria for Diagnosis

It is now generally recognized (1) that the criteria for diagnosis includes history of exposure, consistent clinical or radiological features, presence of granulomas, tissue analysis, and evidence of hypersensitivity.

In the author's view, positive tissue analysis is considered essential. Results of atomic absorption spectrometry, and the qualitative laser microprobe mass spectrometry, LAMMS, (24) were positive in 12 of 13 cases tested. The one patient who tested negative in this test had a positive patch test.

The Role of Sensitivity Tests. [Two hundred fifty-one patients are recently being extensively investigated (26) with the suggestion of identifying preclinical disease. In the present series the beryllium lymphocyte transformation (BeLT) test was positive in two of four patients and the patch test in five of seven, in total seven of nine (70%). Beryllium was detected in both BeLT negative cases.

In this series, all five criteria were satisfied in six patients and the first four criteria in a further six patients. A total of 12 patients are thus classified as definite cases of CBD. Six other patients met the first three criteria were met but they lacked

confirmatory analysis. The BeLT test was negative in one test, not available in the remainder. One had a positive patch test. These six cases are classified as probable, because, despite a history of exposure, sarcoidosis cannot be excluded.

The remaining case is problematic and classified as dubious. The patient, a beryllium air sampler for 12 years and without granulomas, had a positive LAMMS analysis and a negative BeLT test. He suffered from long-standing seropositive rheumatoid arthritis. He exemplifies the truism that any single criterion above is insufficient for diagnosis with the possibility of low, areactive exposure.

Finally, the main pathological differential diagnosis is sarcoidosis (27). Because the gross and microscopic features are identical, the real distinction requires the detection of beryllium in the granulomas and/or scars.

REFERENCES

- Jones Williams W. Diagnostic criteria for chronic beryllium disease based on UK Registry 1945–1991. *Sarcoidosis* 10:41–43 (1993).
- Wood CH, Ball KP, Teare ND. A case of beryllium disease. *Br J Ind Med* 15:209–212 (1958).
- McCallum RI, Rannle I, Verily C. Chronic pulmonary berylliosis in a female chemist. *Br J Ind Med* 18:133–142 (1961).
- Agate JN. Delayed pneumonitis in a beryllium worker. *Lancet* 2:530–533 (1948).
- Editorial. *Lancet* 2:937 (1948).
- Sneddon IB. Berylliosis, a case report. *Br Med J* 1:1448–1449 (1955).
- Sita-Lumsden EG. Chronic beryllium poisoning (two cases). *Proc Roy Soc Med* 52:1045 (1959).
- Norris GF, Peard MC. Berylliosis: report of two cases with special reference to the patch test. *Br Med J* 1:378–382 (1963).
- Sarkar TK, Rhys-Jones E, Lut-Nyche VU. The diagnosis of beryllium lung disease. *Br J Dis Chest* 65:182–185 (1971).
- Chesner C. Chronic pulmonary granulomatosis in residents of a community near a beryllium plant: three autopsy cases. *Ann Intern Med* 32:1028–1048 (1950).
- Slavin P. Diffuse pulmonary granulomatosis in young women following exposure to beryllium compounds in the manufacture of radio tubes. *Am Rev Tuberc* 65:142–158 (1952).
- Lleben J, Jackson AJ. Beryllium oxide poisoning. *Ind Med Surg* 22:507–509 (1953).
- Kllne EM, Moir TW. Long term experience with beryllium disease. *Arch Ind Health* 19:104–109 (1959).
- Barnett RN, Brown DS, Cardoma CB. Beryllium disease with death from renal failure. *Conn Med J* 25:142–148 (1961).
- Sprince NL, Kazemi H, Hardy HL. Current [1975] problems of differentiating between beryllium disease and sarcoidosis. *Ann NY Acad Sci* 278:654–664 (1976).
- Matilla A, Galera H, Pascual E, Carapeto R. Chronic berylliosis. *Br J Dis Chest* 67:308–314 (1973).
- Kuhne W, Ahlendorf W, Hoffman NK. Chronische Berylliose der Lungen Unter Besonderer Berücksichtigung der Pathomorphologie. *Zeit Erkrankungen der Atmungsorgane* 143:263–269 (1975).
- Karkinen-Jaaskelainen M, Maatta K, Pasila M, Saxen L. Pulmonary berylliosis: a report on a fatal case. *Br J Dis Chest* 76:290–297 (1982).
- Williams DW, Jones Williams W. Is sarcoidosis a multisystem disease? An autopsy study. In: *Sarcoidosis, Proceedings of the XII World Congress 9, Suppl 1* (Izumi T, ed) Milan:Edizioni Bongraf, 1992;305.
- Jones Williams W, Kilpatrick GS. Cutaneous and pulmonary manifestations of chronic beryllium disease. In: *Proceedings of Sixth International Conference on Sarcoidosis, 1972, Tokyo, Japan* (Iwai K, Hosoda Y, eds). Tokyo:University of Tokyo Press, 1974;141–145.
- Jones Williams W. The nature and origin of Schaumann bodies. *J Path Bacteriol* 79:193–201 (1960).
- Johns CJ, Paz H, Kasper EK, Baughman K. Myocardial sarcoidosis: course and management. In: *Sarcoidosis, Proceedings of the XII World Congress 9, Suppl 1* (Izumi T, ed). Milan:Edizioni Bongraf, 1992;231–236.
- Hall TC, Wood CH, Stockle JD, Tepper LB. Case data from the Beryllium Registry. *AMA Arch Ind Health* 19:100–103 (1959).
- Jones Williams W, Wallach R. Laser microprobe mass spectrometry (LAMMS) analysis of beryllium, sarcoidosis and other granulomatous diseases. *Sarcoidosis* 6:111–117 (1989).
- Jones Williams W, Williams WR. Value of beryllium lymphocyte transformation test in chronic beryllium disease and in potentially exposed workers. *Thorax* 38:41–44 (1983).
- Kreiss K, Mroz MM, Zhen B, Martyny JW, Newman LS. Epidemiology of beryllium sensitization and disease in nuclear workers. *Am Rev Respir Dis* 148:985–991 (1993).
- James DG, Jones-Williams W. *Sarcoidosis and Other Granulomatous Disease. Series 24, Major Problems in Internal Medicine*. Philadelphia:WB Saunders, 1985.